

Buried but Alive?

Interpreting Post-depositional Bone Movement, Anxieties over Death and Premature Burial

BY SIAN ANTHONY

Abstract

The young, beautiful and wealthy widow Giertrud Birgitte Bodenhoff was buried in Assistens cemetery, Copenhagen on 23 July 1798 but was she dead? Family stories claimed she had been buried alive but was found by grave-robbers who then killed her to conceal their crime. Her skeleton was exhumed in 1953 and the unexpected position of it within the coffin was used to confirm the stories, which echo many similar narratives that betray anxieties over death and premature burial.

With advances in archaeological methods and forensic taphonomy, this conclusion requires reinterpretation. The burial environment is not static and the body and later the skeleton can move while undergoing the decay process. The position of the skeleton in burials excavated in the same cemetery from 2009–11 is used to review the Bodenhoff story. How does decomposition move the bones within a well-preserved coffin? Can some typical movements of bones in coffins be identified in Assistens to advance greater understanding of what happens underground in the coffin?

Introduction

Gothic literature and popular culture are full of premature burials, but the fear of being buried alive is also a long-held fascination in the western world, with stories attested from the Classical period onwards. There was a particular peak of interest in the 18th and 19th centuries (Bondesen 2001, 77 ff.) when fiction inspired medical and legal investigations along with technical solutions to what was regarded as a serious problem. Numerous stories and anecdotes were

collected as evidence that premature burial was a common phenomenon (e.g. Tebb & Vollum 1896). The behaviour of people, as told in the stories, suggests a malleable sense of death where it is a reversible and porous state (Ariès 1981, 609) in contrast to a finite medical state. The veracity of many of these stories is unproven as they share identical features built on repetitive tropes such as *the lady with the ring* (Bondesen 2001, 35 ff.), where unconscious females were awakened

by grave-robbers cutting off a finger to steal a ring (Tebb & Vollum 1896, 276). The stories disproportionately focus on young and beautiful women such as Giertrud Bodenhoff, buried in Assistens cemetery, Copenhagen, but rumoured to be a victim of premature burial and murder. In 1953 the stories related about Giertrud prompted an exhumation by a distant descendant, Viggo Starcke. These stories and interpretations of burials as premature can be viewed as illustrating the fascination with this phenomenon and a continuing sense of uncertainty over death.

The cause of these fears can be related to increasing uncertainty from the 18th century onwards over identifying the moment of death. Death was commonly verified by provoking pain responses, checking for breathing and confirmed through the practice of wakes. A long period of time between death and burial created the ability for people to find their way back to life, if that was possible. It also enabled confirmation of death from the putrefaction of the body. At the same time this lengthy liminal time also allowed grieving, acceptance of death and the renegotiation of social relations after the loss of the person. Previously, in medieval Christian societies anxieties surrounding death may have focussed upon Purgatory, atoning for sins and the possibility of resurrection. Post-Reformation anxieties may be inclined to material and bodily matters and as medical knowledge in Europe developed, practitioners realized that there was uncertainty over the precise point of death. Previously blurred boundaries between life and death included an ability to cross between them, but a strong and defined medical boundary created a need to categorize people as dead or alive. Even today signs of death are not universally agreed (Scarre 2007, 5 ff.). However, it was not only medical knowledge that contributed to understandings of the body; parallel beliefs about the body based on religion, folklore or broader social mores are also noted as contributing towards

the perception of a liminal phase between life and death (Tarlow 2011).

From the 1700s there is evidence of people explicitly taking more technical measures against being buried alive. Waiting mortuaries were built in Europe, including Assistens in 1808 (Lindberg 2010, 90), to watch over the body before burial, but simply waiting for signs of death was not deemed sufficient. The application of more scientific means became fashionable, for example by inventing safety coffins with oxygen tubes or including bells for people to ring (Bondesen 2001, 118 ff.). The 21st-century equivalent involves depositing mobile phones in the coffin, although the motivation may also be symbolic because it replicates the communication that occurred during life (Aggedal 2006). Curiously, both cremation and embalming were suggested as solutions to prevent premature burial (Tebb & Vollum 1896, 225 ff.), and whilst technically correct, these solutions could simply exchange one anxiety for another. Oral histories similar to that of Bodenhoff could have been expressions of these anxieties which were used as evidence of the need to reform the handling of the dead body.

Giertrud Bodenhoff

Giertrud Rosted married Andreas Bodenhoff at the age of 16 in 1796. Unfortunately, only five months later Andreas died, leaving her a childless, wealthy widow. A large family plot with vault and gravestone were then purchased in Assistens cemetery (Fig. 1), a relatively new landscape cemetery established in 1760. Two years later, Giertrud's death on 18 July 1798 was noted in the newspaper *Berlingske Tidende* on 20 July. At this time no formal medical or legal record of death was necessary in Denmark. Giertrud's burial five days later on 23 July is also a matter of record, but it is events after the burial that are of interest here.



Fig. 1. Giertrud Bodenhoff and her husband Andreas's gravestone in Assistens cemetery, Copenhagen, August 2017. Photo by S. Anthony.



Fig. 2. Exhumation within the Bodenhoff vault in 1953. The Royal Library, Denmark.

Stories circulated of how she had been buried unconscious and alive but was awakened by grave-robbers after her funeral. Although differing in specific details, these stories were united in their theme. Two alternatives as to why she woke were proposed: either the robbers had cut off one of her fingers to steal a ring or they had pulled off an earring, bursting an abscess in her middle ear. She was alleged to have begged for help, but the robbers panicked and promptly dispatched her, conclusively this time, with a spade to the head and covered up the crime (Starcke 1954, 26).

Interest in Giertrud Bodenhoff's story was sparked over 150 years later when Viggo Starcke garnered support for an exhumation based on the evidence of the family stories. This took place in January 1953 (Fig. 2) to attempt to determine any evidence for the narrative of premature burial, grave-robbery and murder. The examination was undertaken with the permission of the cemetery and

family descendants with expertise provided by the cemetery staff, police, a pathologist and dentist. Vilhelm Møller-Christensen, a medical historian with an interest in palaeopathology and archaeology, also participated. He had experience of digging medieval shrouded or cist burials. When the vault was opened the coffin was discovered to be under a thick layer of clay. The coffin lid was collapsed, but fragments of the tin alloy coffin plate were found. There were also two iron bands on the lid which had possibly been wrapped around the coffin. The skeleton was uncovered but only one photograph taken of it, partially excavated, which the family requested should not be widely published. A rough sketch was made of what was described as an unusual position for skeletal remains (Fig. 3).

The evidence found was interpreted as supporting the stories of premature burial, grave-robbery and murder. Grave-robbing in

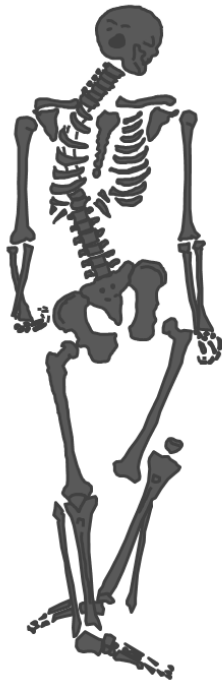


Fig. 3. Field sketch of the position of Giertrud Bodenhoff's skeleton (not to scale). By S. Anthony, redrawn after Starcke 1954, 115.

Assistens is attested in documents (Bidstrup 1973) and archaeologically (Anthony 2015; Anthony 2016, 334), but the focus was on clothes and shrouds, jewellery and coffin wood, not the theft of the body. The poor and fragmented state of the Bodenhoff coffin plate was suggested as the result of being broken by grave-robbers either during the course of their work or to steal the metal. Another factor cited for robbery was the lack of jewellery found in the coffin, only stains being found from a few small decayed hairpins in the hair (Starcke 1954, 101). There was no documentary evidence to indicate the clothing she was buried in, nor was there any archaeological evidence for a shroud or clothing. The suggestion, made by the investigators on the evidence of the family stories, was that the rich widow would have

been buried in fine garments and jewels, and their absence indicated removal.

Anthropological examination of the skeleton, including X-rays of the cranium, confirmed a young adult female, 17–21 years old (Starcke 1954, 103–4). There was an anatomical or congenital anomaly where the lowest (fifth) lumbar vertebra was fused to the sacrum. This is a common feature and if unilateral, which most commonly affects the right side, progressive scoliosis can develop, generating rotation and curvature of the spine (Aufderheide & Rodríguez-Martín 1998, 66). An impacted lower left third molar was suggested as potentially causing a root inflammation (periodontitis) but there was no evidence in the cranium for an abscess. Investigation of the cranium and mandible revealed no evidence for manner of death because there were no indications of any perimortem injury such as a blow to the head. All hand bones were present, although it is uncertain whether they were closely observed enough to reveal any perimortem injury such as a cut to the hand phalanx. The skeleton was reburied in the vault after the examination of 1953, so no further analysis can be undertaken. The skeletal analysis casts doubt on the family stories which had suggested that Giertrud woke up when an earring was pulled from her ear, which burst an abscess in the middle ear, or that a finger had been cut off. There was also no evidence for a blow to the cranium.

However, the most important factor used as evidence for premature burial and murder was the position of the skeleton in the coffin (Starcke 1954, 113 ff.). It deviated from the expected norm – where the body would be laid out on the back (supine) with the upper limbs folded on the torso. Instead, the skeleton was observed to be in a distinctly different position with several notable characteristics (Table I). The cranium and mandible were separated from the vertebrae and the cranium was lying

Table I. Summarized features of Giertrud Bodenhoff's skeleton interpreted as evidence for premature burial and murder.

Skeletal area	Description
Cranium	Inferior aspect uppermost, anterior aspect of the cranium towards the base of the coffin
Vertebral column	Exaggerated curvature to the right
Pelvis	Right <i>ossa coxae</i> positioned caudally compared to the left, resulting in the skeleton being aligned to the right
Upper limbs	Extended upper limbs with fingers curled
Left knee	Displaced upwards (elevated) in relation to the femur, as if the knee is raised
Left foot	Inferior with respect to the right tibia and fibula, the foot is below the right lower limb

face down by the left shoulder. The position of the cranium was suggested by Starcke as indicating strangulation as a cause of death. The vertebral column was curved dramatically with upper limbs extended by the sides and hands appearing to show curled fingers. The left tibia and fibula, in articulation, were displaced, as if flexed, and in the sketch the left foot is shown as underneath the bones of the right tibia and fibula. There were discrepancies between the photograph and sketch; the position of the left foot in the photograph is not visible and the left tibia is even further superiorly positioned, in relation to the left femur shaft, than the sketch suggests. The sketch itself was not drawn to a scale, and comparing the uneven limbs, particularly the length of the forearms, or length of the feet indicates that it was not an accurately measured observation. The unusual position of the skeleton was compared, by Vilhelm Møller-Christensen, to others excavated in his career. He had previously observed cranial displacement, extended upper limbs and knee movement in two separate burials which he associated with some unusual activity: death by hanging or being buried alive (Starcke 1954, 116). This interpretation based on skeleton position is strongly reminiscent of Gothic and popular-culture narratives of a person alive and struggling within a coffin.

Overall, the details from the family stories

and documentary research were combined with the results of the exhumation, which left Starcke under no personal doubt that the main elements of the stories were correct, but suggesting instead that strangulation or asphyxiation was the cause of death, based on the rotation of the cranium. However, doubts about the interpretation were raised by another family member long before the exhumation (Lange 1914), and afterwards, by a historian (Fabritius 1955). Yet the story spread widely and continues to be used as scientifically confirmed evidence of a premature burial and as a fascinating example of frightening events in a cemetery (Starcke 2010, 37 ff.).

Taphonomic advances in burial interpretation

At the time of the investigation in the 1950s, there was only one other suggested interpretation of premature burial at the medieval Æbleholt monastery in Jutland, Denmark (Møller-Christensen 1958). Other premature burials have since been suggested; at the Holy Trinity Church in Coventry, UK, premature burial was interpreted from the right upper limb of a skeleton being flexed whilst the left hand was placed up by the head (Soden 2000). Another example is the Anglo-Saxon burial from Sewerby, UK, with a

skeleton in a contracted position (Hirst 1985, 39 f.). This interpretation has been reassessed as potentially the consequence of death from fire where the muscles contract, thus maintaining the body in an unusual position (Knüsel *et al.* 1996, 121 f.). The common evidence used for interpretation is the posture of the skeleton; specifically the position of limbs which are interpreted as having shown signs of struggle within the coffin. They deviate from what was the expected position of someone laid out in a coffin, supine with extended lower limbs and the feet placed together with the upper limbs across the body. However, there is variation in position of the upper limbs over time and between geographical regions. The upper limbs can be extended by the sides, or with the hands placed on the thighs or even upon the chest mimicking a prayer position. That the body position or skeletal elements may move over time after burial must also be factored into the interpretation. Is deviation from the expected posture a good foundation for interpretation of premature burial?

Understanding the processes occurring in the burial environment has greatly advanced over the last decades; research has been undertaken from forensic and archaeological perspectives (e.g. Dirkmaat 2012). Taphonomic research examines how the physical materials that comprise the burial chemically and materially decay and how they interact in this process (Magnell 2008, 121). The body is an obvious focus but the coffin and objects within it, the soil, gases within the soil, pH levels and ground water all impact how the burial decays. The processes of decomposition create gases, liquids and even conversion into adipocere. The consequences of this dynamic environment are that the body and bones can move within the coffin space, skeletal elements disarticulate and fall to the coffin base or against the coffin sides. The bones will not always remain in the same anatomical position as they once did in the living body.

The archaeothanatological approach developed by Henri Duday (e.g. Duday & Guillon 2006) concentrates upon recording the precise positioning of bones within the burial context, which enables reconstruction of the original position at deposition and any potential secondary manipulation. This is primarily applied to shrouded and earth-filled prehistoric and medieval burials but is also applicable to historic burials which have a coffin (Pokines *et al.* 2016). Bodies that are wrapped in a close-fitting shroud and then covered in soil will have a limited amount of space for bones to move within, essentially just the space created by the decomposition of the body – the initial volume of the cadaver (Nilsson Stutz 2003, 254). Ribs can fall down within the torso area but will not spread beyond the original limits once occupied by the body. Soil will eventually fall within that space too, and for example, hold the small bones of the hand in articulation. Coffins, however, protect the body from surrounding soil, thus creating a void. Extensive movement of the bones is possible; they are unstable because there is space where bones may fall.

A great number of factors therefore affect the position of coffined human remains during the transition from a fleshed to a skeletonized body. The decomposition processes of the body are modified by the coffin, particularly if it does not collapse. Bedding material, a mattress, clothing or perhaps shoes may restrict movement and affect the speed and manner of decomposition. For example, where there is no support for the cranium, it may rotate, which can cause significant movement of the mandible and superior elements of the vertebral column. Movement of human remains can also be impeded by the coffin; if the body rests directly against the coffin side, then the movement of the bones can be limited (a wall effect, Knüsel 2014, 34) This effect has been used to determine the presence of hard and soft containers in burials where

all of the material has decayed (Nilsson Stutz 2003). Where there is space around the body, there is more room for movement by small animals and insects. Fluctuating water levels can also make smaller bones or objects such as dentures float within the coffin and settle in unexpected places. Human intervention by gravediggers or grave-robbers may also move the body around within an intact coffin.

However, if the coffin lid breaks rapidly from the weight of the soil, then the coffin will fill with earth and wrap around the body, impeding movement as it decomposes. This scenario may also speed up decomposition by the introduction of bacteria and small insects within the soil (Garland & Janaway 1989, 27). A coffin space can also be filled slowly in small increments as the coffin breaks down, with soil and roots entering the space, creating variable or contradictory features of bone movement. Despite these variables, the decomposition of the body does follow some regular processes, with some joints and articulations being more persistent and stable than others (Roksandic 2002, 103 f.), meaning they will remain in articulation longer. The incremental filling of the coffin can therefore be attested to by the disarticulation of certain joints but not others.

Three major characteristics have been associated with the decay of a body inside an intact coffin (Roksandic 2002). The first is that soft tissue decay enables both sides of the *ossa coxae* (the iliac blades of the pelvis) to flatten and fall down onto the coffin base, resulting in the separation of the pubic symphysis. The second characteristic is that the acetabulofemoral joint within the pelvis decays quickly and the femur falls down and causes the whole bone to rotate laterally towards the side of the coffin. The third characteristic is that the position of the patella is affected by the rotation of the femur; this causes the bone to slide from its anatomical position on the femoral condyle. Finding a patella in its original position would require soil packing or clothing to secure it in

anatomical position. In prehistoric or medieval burials the utility of these characteristics is to identify the presence of a coffin or other container surrounding the skeleton, even if there were no visible signs of wood or metal corrosion stains in the soil. This is clearly not necessary if the coffin is still preserved. The utility of this research is to contribute towards the analysis of how the body, and after decay the skeletal remains, can move within the space of the coffin, how it can be enabled or restricted by clothing, coffin furnishings or the side of the coffin to result in the skeletal position recorded during excavation.

Understanding typical skeletal positions in Assistens

Excavation of part of Assistens from 2009 to 2011 provided an opportunity to examine the position of skeletons within intact coffins (Anthony *et al.* 2016; Anthony 2016). Almost 1000 coffins and urns were removed to construct a new Metro station in the north-eastern corner of the cemetery. The coffin burials date from the 1810s to the 1980s and the good preservation levels enable analysis of how the position of the body, and later the skeleton, can move within the coffin over time. Although these burials are later in date than Giertrud Bodenhoff's, they are in the same cemetery with comparable soil environments and subject to similar cemetery working practices. Position in the coffin was consistent in Assistens, with virtually all bodies laid out supine with extended lower limbs. Upper limb position is more varied, either being placed along the sides of the body or on the body placed on the thighs, abdomen or chest. Over half the burials at Assistens had the upper limbs extended by the sides (Anthony 2016, 218). Shrouds were rare but clothing or other coverings, such as blankets, were used. Pillows or mattresses which held the body in

position were more commonly found in the later 19th century (Anthony 2016, 245).

Bodenhoff's burial was within a brick vault, later filled with clay, which could have protected the remains more than an earth-covered burial. Few excavated burials were in vaults and many were truncated or disturbed so a sample of earth-covered burials was chosen for comparison which were undisturbed by later burial activity. The 73 burials used for the sample all have a coffin that was intact and undisturbed on all four sides, the base and the lid. Of these 73, 11 were omitted from the analysis because they were sealed coffins, had significant soft tissue remains which obscured the skeleton or were juveniles, leaving 62 adult skeletons for comparison. The analysis was completed post-excavation from photographs taken after removal of the coffin lid and clearance of any soil around the skeleton. The written descriptions of the coffin and skeleton were also compared for any further details recorded by the excavating archaeologist (Anthony *et al.* 2016). Therefore a comprehensive archaeoanthatology analysis has not been possible, but some common observations derived from the approach were used as inspiration for this analysis.

Of the 62 burials, 33 (53%) had evidence for post-depositional movement of bones in the coffin. Even within intact coffins there was a range of variation. Of the three major characteristics of intact coffin burials, observations recorded the flattening of the *ossa coxae* in only six burials; it is suggested instead that the skeletal remains were restricted by clothing or packing around the body. Lateral rotation of the femora occurred in 23 of the 66 instances recorded (35%). Lateral rotation did not always occur bilaterally; one lower limb was often stabilized by a coffin wall. Finally, although the precise position of very few patellae could be ascertained in the images, only six burials were observed with the patellae no longer in correct anatomical position.

Other features were noted, such as nine burials where the crania had disarticulated from the cervical vertebrae and rolled to one side or completely rotated. Of these, four burials had no evidence for pillows and the amount of movement suggested inadequate or thin mattresses. In the five burials with pillows, the crania had severely rotated. A further six burials with pillows showed no movement. This suggests that the presence of a pillow can influence movement in two ways; first by enhancing any angle of the head and enabling extreme movement or by cushioning the head to stabilize it. The cranium and mandible can detach early in the decay process from the vertebral column (Roksandic 2002, 102) and this effect can be exacerbated if the pillow decays.

There were few documented examples of movement in the upper limbs. These limbs appear to have been stabilized by the coffin sides and clothing. Collapse of the coffin base resulted in rare examples where the upper limbs were retained at a higher level than the torso. One example contained a displaced left humerus, where the distal end lay over the anterior aspect of the cranium (the face) and the proximal end over the xiphoid process of the sternum. This is suggested as the result of the coffin walls collapsing inwards, pushing the humerus into the centre of the coffin. This must have occurred when the remains were almost fully skeletonized as there was no movement observed of the scapula, radius or ulna. In two burials there was also movement of the ulna and radius where laterally displaced bones may have been caused by the accumulation of gases within the torso during the process of decay. There were also three burials where the ulna and radius were separated from their normal anatomical relationship.

Materials inside the coffin including pillows, mattresses, packing or clothing can hold the body *in situ* during decay, but the

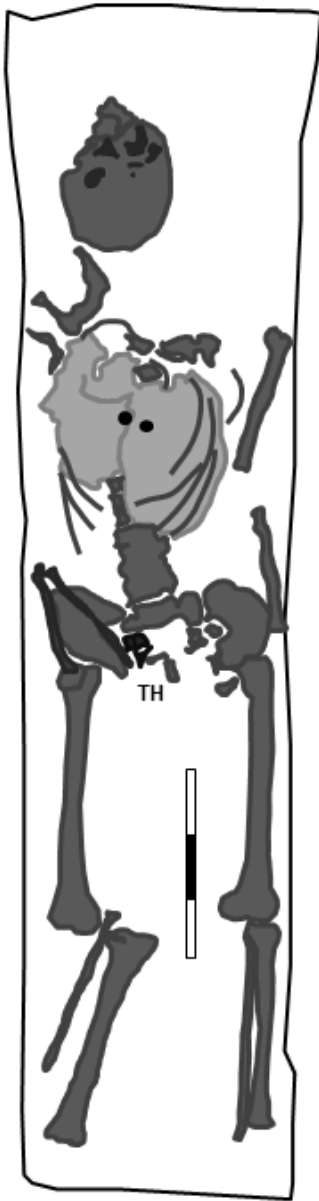


Fig. 4. The torso is held together by clothing but disarticulated cervical and thoracic vertebrae (TH) were found displaced within the coffin. Other characteristics noted are the rotated cranium and displaced left humerus. The *ossa coxae* are flattened and the right ulna and radius are separated. The right femur is rotated laterally and disarticulated from the tibia and fibula, but the left lower limb is stabilized against the side of the coffin. Burial G1413, showing the outline of the coffin, Assistens cemetery. By S. Anthony.

effect can vary within the coffin. One burial contained remnants of a shirt which held together most of the torso but individual vertebrae and some ribs were also displaced within the coffin (Fig. 4). Another feature observed in eight burials within the sample was flattening of the ribs beyond the liminal void of the body.

There was evidence of movement of the body when it was fully articulated, 14 burials showed that the body could slide in the coffin either during transport to the cemetery or when being lowered into the grave. Where the body had slid down in the coffin, the feet would be pushed flat against the end of the coffin. The lower limbs were flexed and there was an exaggerated curvature of the vertebral column (Fig. 5) with the cranium displaced towards the shoulders. In six cases the body had slid to one side of the coffin which trapped one side of the body and kept it stabilized during decay, allowing bones in the other side more space for movement. Sliding in the coffin is associated with exaggerated vertebral curvature; six out of the nine burials observed with exaggerated vertebral curvature had also slid in the coffin. The vertebral column acted as a unit, indicating that this movement took place while soft tissue and ligaments were present. Of the nine burials with unusual curvature of the vertebrae, many were older adults with vertebral degeneration, osteoarthritis or congenital fusion of the vertebrae (Fig. 6).

Another characteristic feature noted was disarticulation of the distal femur and proximal tibia and fibula. The knee is considered as a persistent and robust joint (Knüsel 2014, 32), and it is affected by the lateral rotation of the femora but the tibia and fibula do not always move with the femora. They become detached and stay *in situ* or become displaced at a different angle. Movement tended to be bilateral and was observed in 13 burials. There were many variations with the tibiae

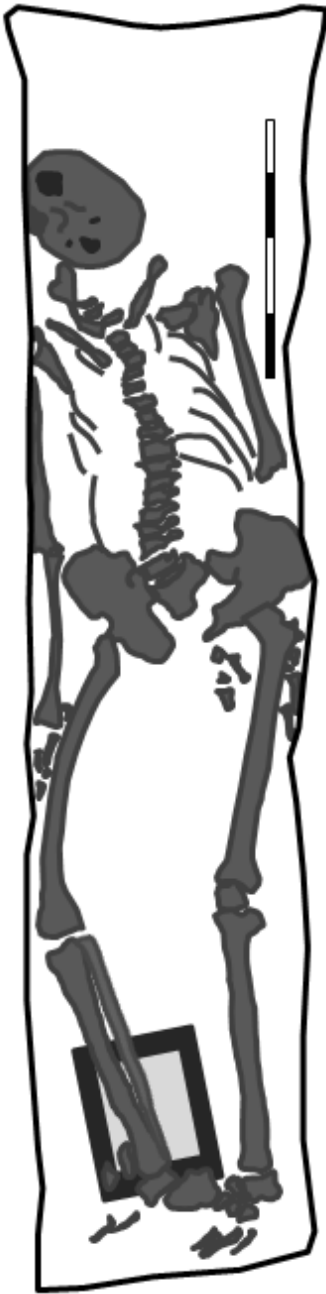


Fig. 5. Curvature of the vertebral column from the body sliding to the right side of the coffin, note also the rotation of the cranium. The right lower limb may have been flexed superiorly to allow a wooden photographic frame to fall underneath. Note also the flattened *ossa coxae*. Burial G1141 showing the outline of the coffin, Assisens cemetery. By S. Anthony.

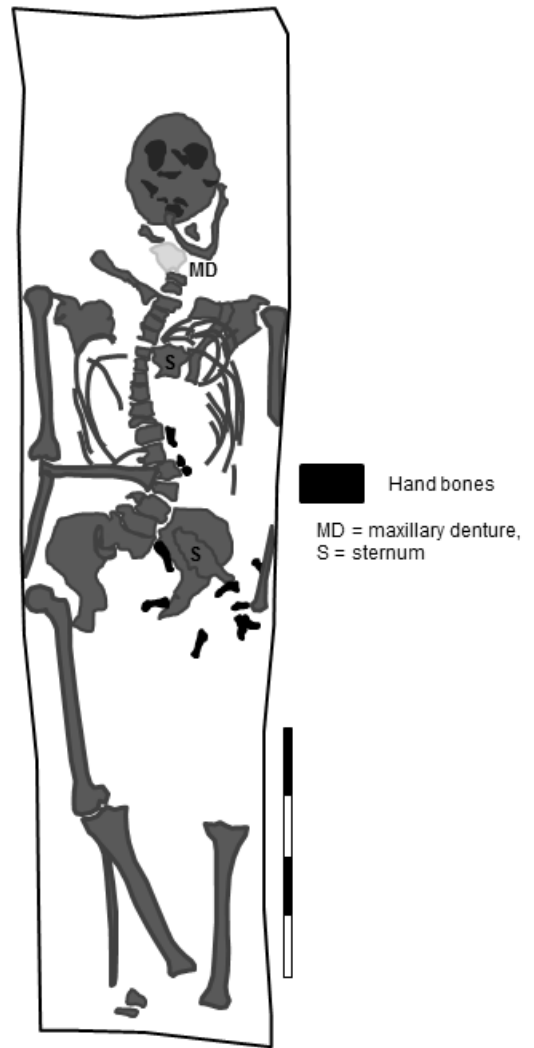


Fig. 6. The position of the skeleton illustrates an extreme curvature of the vertebral column, exacerbated by scoliosis and osteoarthritis in the lumbar vertebrae and collapse of the thoracic vertebrae but also by the body sliding downwards in the coffin. Note also the rotation of the cranium, separation of the right forearm bones, lateral rotation of the right femur, and disarticulation and movement of the right tibia (but not the right fibula). Burial G1071 showing the outline of the coffin, Assisens cemetery. By S. Anthony.

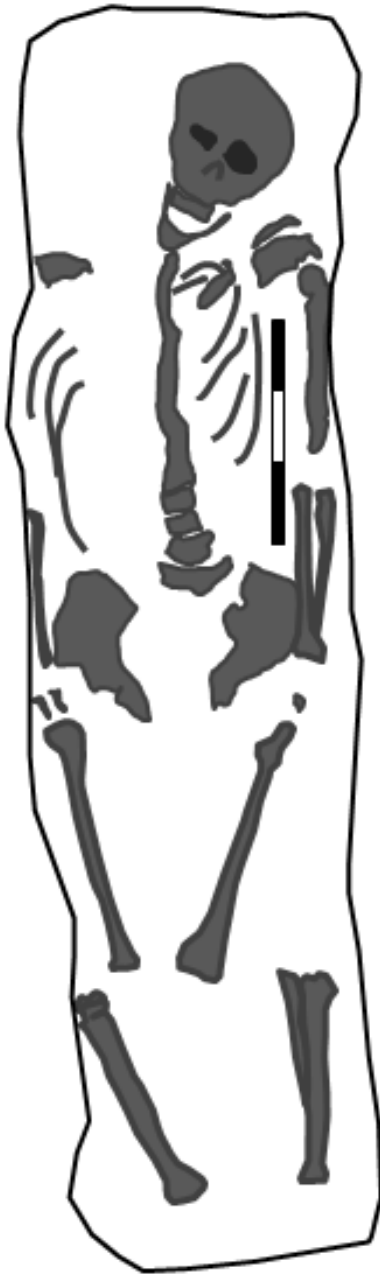


Fig. 7. An extreme variation of the post-depositional movement of elements of the lower limbs with the femora separated from the tibiae when the femora rotated. Note also the flattened *ossa coxae* and the upper left limb of the skeleton which is stabilized against the side of the coffin. Burial G1315 showing the outline of the coffin, Assistens cemetery. By S. Anthony.

and fibulae displaced anteriorly and elevated, overlapping with the femora, or displaced at an angle to them (Fig. 7). The tibia and fibula could also be found separated from each other and from the foot at their articulation with the ankle. There was little post-depositional movement observed in the feet suggesting that it was common for textile to be wrapped around them. Shoes may also have been used, but few have been found and stockings or socks appear to be more common (Cherryson *et al.* 2012, 28–30; Anthony 2016, 230).

Another important feature of intact coffins is their ability to retain liquids, such as decomposition fluids from the body or ground water seeping into the coffin. Parts of the Assistens cemetery were waterlogged and the deepest coffins were affected with smaller bones, particularly ribs, vertebrae and hand and foot bones being moved within the coffin. Seven coffins had evidence for smaller bones floating around the coffin.

Buried alive?

With the comparative evidence of these 33 burials we can reassess the interpretations which are based upon the position of Giertrud Bodenhoff's skeleton. The body was laid supine but the position of the upper limbs is unknown. It is likely that a mattress, pillow and clothing were provided. The presence of jewellery cannot be confirmed through copper staining on the skeleton, but there may have been jewellery which was removed. Comparable early and elaborate burials in Assistens suggest a shroud rather than everyday clothing but contain little or no jewellery (Anthony 2016, 230 ff.). The evidence suggests that the body slid in the coffin when lowered into the vault, twisting the torso and resulting in an exaggerated curve of the vertebral column exacerbated by the fused joint between lumbar vertebra

and sacrum. Curvature of the spine may have been missed by the anthropologists as very few individuals with this condition exhibit skeletal changes (Aufderheide & Rodríguez-Martín 1998, 66). The lower limbs flexed at the knee and the cranium rolled to one side.

It is at, or around, this point that the body could have been searched for valuables by grave-robbers, disturbing the torso, upper and lower limbs to remove clothing, the hands for a ring or moving the head to search for earrings and necklace. There would be no reason to straighten the body after this. Possibly a pillow was stolen, thus further rotating the cranium and mandible to the left and the vertebral column to the right. This would also have caused the pelvis to further shift in the same direction. The position of the left lower limb could have been exaggerated by these actions and then supported by the side of the coffin, moving the foot under the right tibia and fibula as suggested by the sketch. The right lower limb may also have been lifted up slightly. The upper limbs may have been moved and fallen to each side with the hands remaining in a flexed position after having been searched for rings. While this is possible, equally there is no direct evidence for grave-robbery.

As soft tissue and any coffin furnishings decay, several of these displacements become more exaggerated. The cranium rolls so that its base, with the foramen magnum visible, is uppermost. This was recorded in other coffins, particularly where pillows or head supports were used but then decayed. Vertebral curvature could have been exaggerated by the resistance of the fused lumbar vertebrae-sacrum further pulling the pelvis to the right. The *ossa coxae* fell flat to the base of the coffin and the femora rotated laterally, suggesting that decay took place in a void space which was not rapidly filled with soil. Although the sketch shows the right patella *in situ*, the photograph does not. Both feet

may have been further displaced by rotation of the femora but are generally seen to be in anatomical order, suggesting the continued presence of textile or clothing.

Decay and collapse of the coffin, particularly the lid, is the final major factor affecting post-depositional movement causing considerable movement of the bones. Excavations of historic churchyards and cemeteries show that coffin lids and tin coffin plates can be very poorly preserved (Henderson *et al.* 2013, 74 ff.). When the coffin lid collapsed, so did the two iron bands around the coffin, of which only one other example was observed in Assistens, but this has also been recorded in the UK (Cherryson *et al.* 2012, 150). The bands were recorded as located over the shoulders and knees. The weight of the coffin lid, iron bands, and the soil could have altered the placement of the knees considerably. This may explain the movement of the right fibula which was superiorly displaced from its normal anatomical position. This position is clearer in the photograph than in the sketch. If both knees were slightly raised and leaning against the sides of the coffin and were then pushed down, combined with the processes described, it could result in the position of the skeletal remains observed by excavators in 1953.

Although the Bodenhoff investigation was undertaken with the highest standards of the day, over 60 years later there have been significant advances in the knowledge of burial environments which enable reinterpretation of the original conclusions. Premature burial is an unlikely interpretation based upon the position of the skeleton. Overall, the analysis of comparable burials at Assistens shows that most of these bone movements observed in Bodenhoff's coffin are also present within well-preserved coffins. The most unusual feature is the placement of the left foot under the right tibia and fibula, which is only attested in the sketch, but not clearly in the only photograph

of the skeletal remains. This highlights one of the problems of attempting analysis from secondary sources, long after the fieldwork has taken place, where the sketch and the photograph differ. This feature has not been observed in the small sample examined here, or in an initial examination of other burials from Assistens. However, neither is it conclusive for evidence of grave-robbery. There was also no archaeological evidence for murder; movement of the cranium is demonstrated as a natural consequence of decay of the body, not strangulation or asphyxiation. The interpretation of grave-robbery is possible, but not proved based upon the post-depositional manipulation of the body. The influence of contemporary popular culture may have created the original stories and influenced the original interpretation, but advances in forensic taphonomy and archaeological knowledge now suggest a more nuanced and evidence-based interpretation.

Conclusions

Far from being a place of rest, a coffin is a very active environment. Natural processes of decay in a burial and the collapse of the grave have the ability to move the body, or parts of the skeleton, into unexpected positions. The three central characteristics of the decay of a body in an intact coffin were present in the sample but were affected by the preservation of clothing, soft coffin furnishings or the sides of the coffin holding the bones in anatomical position. The potential for other characteristics of movement were also highlighted, particularly the displacement of the knee joint, sliding in the coffin and vertebral curvature. Smaller bones displaced by water in the coffin and the rotation of the cranium could also be further researched to interpret post-depositional movement within the active coffin environment.

Although this is only a preliminary study of a small sample of all of the burials excavated at Assistens and it is limited by the analysis being retrospective rather than undertaken on *in situ* burials, it has a wider relevance. The highly contingent and interactive factors involved in any one single burial require caution when interpreting them, but can be used to understand the general environment of coffin burials as well as to highlight unusual post-depositional movements that could point to human activity, or even being buried alive.

Stories of premature burial helped to situate the anxieties and fear surrounding death, and they created a parallel narrative to medical opinions and the expectations of ordered and rationalized modern cemeteries. A good story like Giertrud Bodenhoff's is unlikely to be forgotten, nor should it be. Instead of a confirmed case of premature burial, it can be used as an expression of society's fascination and fear with the subject in a period of anxiety over medical and social death.

Acknowledgements

The Museum of Copenhagen for permitting access to the Assistens archive. The Royal Library, Denmark, for providing an image, and Assistens Kulturcentret for aid in tracking down images and permissions.

References

- Aggedal, J.-O. 2006. En necessär i kistan – något om människors och kyrkans trostolkning i väntan på en större undersökning. In Gunner, G. (ed.), *På spaning... Från Svenska kyrkans forskardagar 2005*. Stockholm.
- Anthony, S. 2015. Hiding the body: ordering space and allowing manipulation of body parts within modern cemeteries. In Tarlow S. (ed.), *The Archaeology of Death in Post-Medieval Europe*. Online. Available from: <https://www.degruyter.com/view/books/9783110439731/9783110439731-009/9783110439731-009.xml>. [Accessed 15 May 2017].
- 2016. *Materialising modern cemeteries. Archaeological narratives of Assistens cemetery, Copenhagen*. Lund Studies in Historical Archaeology 18. Lund.
- Anthony, S., Keenan, S., Winther Johannsen, J., & Jørgkov, M. L. 2016. Assistens Kirkegård, Copenhagen. Archaeological Report No. KBM3830. Copenhagen.
- Ariès, P. 1981 [1977]. *The Hour of Our Death. The Classic History of Western Attitudes toward Death over the Last One Thousand Years*. New York.
- Aufderheide, A. & Rodríguez-Martín, C. 1998. *The Cambridge Encyclopedia of Human Paleopathology*. Cambridge.
- Bidstrup 1973. Skandale på Assistens. *Skalk* 4.
- Bondeson, J. 2001. *Buried Alive. The Terrifying History of Our Most Primal Fear*. London.
- Cherryson, A., Crossland, Z. & Tarlow, S. 2012. *A Fine and Private Place. The Archaeology of Death and Burial in Post-Medieval Britain and Ireland*. Leicester.
- Dirkmaat, D. (ed). 2012. *A Companion to Forensic Anthropology*. Maldon, MA.
- Duday, H. & Guillon, M. 2006. Understanding the circumstances of decomposition when the body is skeletonized. In Schmitt, A., Cunha, E. & Pinheiro, J. (ed.), *Forensic Anthropology and Medicine. Complementary Sciences from Recovery to Cause of Death*. Totowa.
- Fabritius, A. 1955. *Personhistorisk Tidsskrift* 13 (3).
- Garland, N. & Janaway, R. 1989. The taphonomy of inhumation burials. In Roberts, C., Lee, F. & Bintliff, J. (eds.), *Burial Archaeology. Current Research, Methods and Developments*. BAR British Report 211. Oxford.
- Henderson, M., Miles, A. & Walker, D. 2013. 'He being dead yet speaketh.' *Excavations at three post-medieval burial grounds in Tower Hamlets, east London, 2004–10*. Museum of London Monograph 64. London.
- Hirst, S. 1985. *An Anglo-Saxon Inhumation Cemetery at Sewerby, East Yorkshire*, York University Archaeology Publication 4. York.
- Lange, N. 1914. *Den Bodenhoffske slægte bog*. København.
- Lindberg, K. 2010. Bygninger på Assistens Kirkegård 1760–2010. In Helweg, S. & Linnée Nielsen, M. (eds.), *Assistens 250*. København.
- Knüsel, C. 2014. Crouching in fear. Terms of engagement for funerary remains. *Journal of Social Archaeology* 14 (1).
- Knüsel, C., Janaway, R. & King, S. 1996. Death, Decay, and Ritual Reconstruction. Archaeological Evidence of Cadaveric Spasm. *Oxford Journal of Archaeology* 15 (2).
- Magnell, O. 2008. Tafonomi – läran om kvarlevornas historia. In Lynnerup, N., Bennike, P. & Iregren, E. (eds.), *Biologisk Antropologi med Human Osteologi*. København.
- Møller-Christensen, V. 1958. *Bogen om Æbleholt Kloster*. København.
- Nilsson Stutz, L. 2003. *Embodied Rituals & Ritualized Bodies. Tracing Ritual Practices in Late Mesolithic Burials*. Acta Archaeologica Lundensia. Series in 8°: 46. Stockholm & Lund.
- Pokines, J., Prince Zinni, D. & Crowley, K. 2016. Taphonomic patterning of cemetery remains received at the Office of the Chief Medical Examiner, Boston, Massachusetts. *Journal of Forensic Sciences* 61 (S1).
- Roksandic, M. 2002. Position of skeletal remains as a key to understanding mortuary behaviour. In Haglund, W. & Sorg, M. (eds.), *Advances in Forensic Taphonomy, Method, Theory, and Archaeological Perspectives*. Boca Raton & London.
- Scarre, G. 2007. *Death*. Stocksfield.
- Soden, I. 2000. *A typical English churchyard?* Available from: <http://www.buildingconservation.com/articles/churchyard/churchyard.htm>. (Accessed 15 April 2017).
- Starcke, G. 2010. Mysteriet om Giertrud Birgitte Bodenhoff. In Kulturcentret Assistens (ed.), *Midt i verden i 250 år. Assistens 1760–2010*. København.

- Starcke, V. 1954. *Giertrud Birgitte Bodenhoff's mysterium*. København.
- Tarlow, S. 2011. *Ritual, Belief and the Dead in Early Modern Britain and Ireland*. Cambridge.
- Tebb, W. & Vollum, E. P. 1896. *Premature burial and how it may be prevented, with special reference to trance, catalepsy, and other forms of suspended animation*. London.

Sian Anthony, Department of Archaeology and Ancient History, Lund University, Box 192, 221 00 Lund, Sweden, sian_victoria.anthony@ark.lu.se.

